

Laser treatment of dentine hypersensitivity

An overview III

Authors_Dr Ute Botzenhart, Dr Andreas Braun & Prof Matthias Frentzen, Germany

_Introduction

More than two decades ago, laser applications in the treatment of dentine hypersensitivity were introduced to dentistry. Many clinical studies using different laser types have been published since. This overview summarises the basic and clinical aspects, including treatment protocols.

In the first issue of laser, conventional approaches towards the treatment of dentine hypersensitivity were discussed with regard to a set of criteria for a successful treatment as proposed by L. I. Grossman (1935). The authors came to the conclusion that, so far, no conventional therapy has been able to meet all the criteria. The authors then moved on to studies on laser treatment. Studies on GaAlAs laser and He-Ne lasers were introduced and analysed. Part I of this article was finished by a comparison between He-Ne lasers and Nd:YAG lasers. Part II in this year's second issue of laser continued with studies on Nd:YAG-laser treatment, Er:YAG lasers. The third and last part of this extensive study gives insight into the workings of CO₂ lasers and sums up important aspects of laser treat-

ment of dentine hypersensitivity in a final conclusion on laser treatment of dentine hypersensitivity.

_Middle-output power lasers: CO₂ laser

The CO₂ laser with a wavelength of 10.6 μm also belongs to the group of the middle-output power lasers. It is easily absorbed by tissues with a high water content, presenting superficial penetration (Romano et al. 2011), none penetrating beyond 0.1 mm (Silberman et al. 1994). Its effect is based upon the closure or narrowing of the dentinal tubules and a reduction in dentine permeability (Gholami et al. 2011; Romano et al. 2011; Moritz et al. 2006; Kimura et al. 2000b; Zhang et al. 1998; Pashley et al. 1992; Bonin et al. 1991). Most effects are explained by laser dehydration, protein destruction and carbonate evaporation (Lin et al. 2000a).

Moritz et al. (1995, 1996, 1998, 2006) described two ways to apply the CO₂ laser to the therapy of dentine hypersensitivity: the direct method, that is CO₂ laser application alone (Moritz et al. 2006); and the indirect method, that is the combination of laser application and fluoridation (Moritz et al. 1995, 1996, 1998). The output power for both methods is approximately 0.5 to 1 W (cw). Irradiation time is approximately 0.5 to five seconds, with a repetition rate of five to ten pulses (Moritz et al. 2006).

The direct method

With the direct method, the use of the CO₂ laser at moderate energy density, the sealing of the dentinal tubules in terms of a narrowing or reduction in their permeability can be achieved (Lan et al. 1999). Silberman et al. (1994) hypothesised that CO₂ lasers enhance the retention of the smear layer, which is partly

Fig. 1 _Hypersensitive dentine with SnF₂ gel layer.

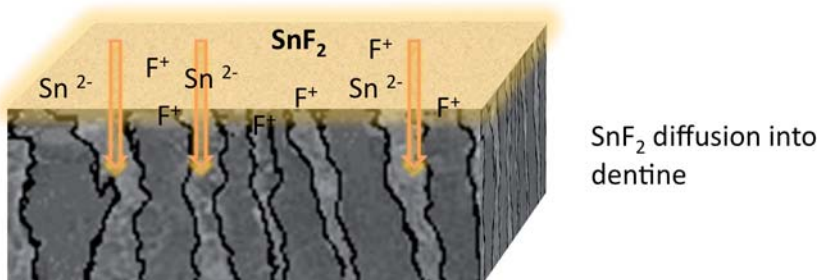


Fig. 1

Fig. 2 CO₂-Laser application through the SnF₂ gel layer.

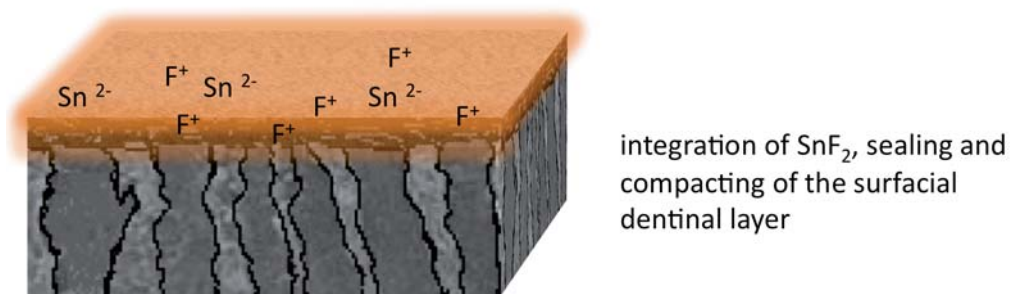


Fig. 2

responsible for the successful desensitisation of hypersensitive roots. Like other wavelengths, the CO₂ laser light can also cause a desiccation of dentine and a temporary clinical alleviation of symptoms (Bonin et al. 1991). With an application of 0.3 W for 0.1 seconds, the sealing depth is about 2 to 8 μm (Fayad et al. 1996). As for the *in vivo* application of CO₂ laser light in dogs and monkeys, no thermal damage to pulpal tissue could be detected at an output power of 3 W and in cw mode for two seconds (Kimura et al. 1998), but morphologically, parameters above 1 W (cw, non-contact mode, without cooling) led to carbonisation and cracks in human dentine, making it unfeasible for clinical procedures (Romano et al. 2011). González et al. (1999) too observed that CO₂ laser application to human dentine at 2 W and 10 J for 0.2 seconds and 25 pulses led to varying effects in SEM examinations, for instance charring, cratering, poring, fissuring, fracturing, cracking and localised melting processes or complete disorganisation of the dentinal structure without sealed dentinal tubules. In several studies, melted areas, probably composed of melted hydroxyapatite were detected inside or around the crater formation after CO₂ laser application. This is due to the high temperature gradient that occurs at the surface (Romano et al. 2011; Lin et al. 2000a). PIXE resulted in a decrease in calcium and an increase in the phosphorous content of the dentinal surface treated, compared with controls, indicating changes in the hydroxyapatite crystal structure (González et al. 1999).

Side-effects

In a study by Zhang et al. (1998), the efficiency of CO₂ lasers in the therapy of dentine hypersensitivity *in vivo* and potentially damaging thermal effects at the dental surface were evaluated over a period of three months. Dentine hypersensitivity was determined by thermal stimuli with cold air and VAS score. Immediately after laser application and after one week, two weeks, one month and three months, hypersensitivity was re-evaluated. Laser light was applied to the affected area with an output power of 1 W in cw mode for five to ten seconds and non-contact mode at a right angle with water-cooling. Each application of

0.5 seconds was followed by a break of five seconds. The procedure was repeated as long as the patient was free of pain. The application time for each tooth was five to ten seconds overall. Patients who had not been free of pain after one week were retreated under the same parameters (Zhang et al. 1998). After three months, 50% of the treated tooth necks were no longer hypersensitive. An interesting phenomenon is that all teeth were free of pain directly after the laser application, but hypersensitivity returned already after one week in nearly 50% of the cases (Zhang et al. 1998). The pain relief directly after laser application can be explained by the anaesthetic effect of laser or the obturation of tubules by denatured proteins from the dentinal fluid, but there are no reports of nerve analgesia as a result of CO₂ laser application (Zhang et al. 1998).

One possible explanation for the recurrence of symptoms is that the CO₂ laser application did not close the dentinal tubules completely and/or durably (Zhang et al. 1998) or that the melted dentinal surface was abraded, for example by tooth brushing (Pashley et al. 1992). In the study, as described above, the parameters chosen did not damage the pulp. All of the teeth were sensitive to electrical stimuli. The study demonstrates that the CO₂ laser, if used with adequate water-cooling, can be helpful for the therapy of dentine hypersensitivity without thermal damage to the pulp. Coleton (1998) reported a success rate of more than 60% using the CO₂ laser for the reduction of post-operative sensitivity of root surfaces after periodontal surgery. He did not observe any side-effects.

The indirect method

The indirect method is based upon the idea of combining the advantages of laser and fluoride therapy, thereby achieving as durable a result as possible. First, fluoride is applied onto the cleaned tooth-neck area. Then laser light is applied through this gel layer. By combining these two methods, the integration of fluoride into the dentine surface should be enhanced (Figs. 1–3).

Moritz et al. (1996) analysed the efficiency of this combined therapy compared with fluoride applica-

Fig. 3 Sealed surface after CO₂-Laser irradiation (indirect methode).

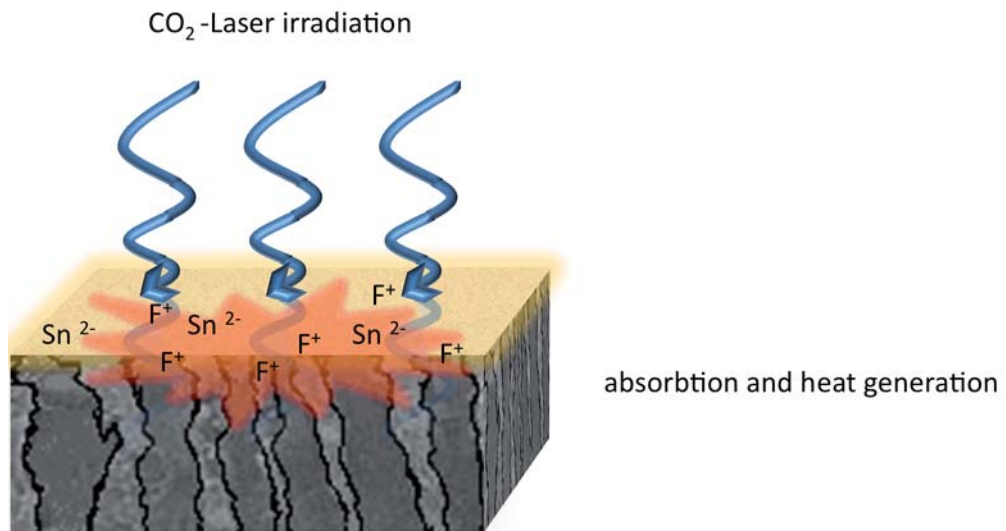


Fig. 3

tion alone, over a period of twelve weeks. Before laser application, a layer of SnF₂ of 10 μm thickness was applied, and then the dentine was irrigated at an output power of 0.5 W in cw mode for five seconds followed by a break of 20 seconds and subsequently a repeated laser application for five seconds (Moritz et al. 1996). This procedure was repeated until each patient had undergone laser application for 30 seconds. Patients who were not free of pain after the first recall were re-treated under the same parameters. The control group was treated with SnF₂ exclusively.

After one week, two weeks, four weeks, six weeks and three months, dentine hypersensitivity was measured again. In combination with VAS, the subjective patient response concerning pain response to specific stimuli was used as an indicator, for example to contact, cold, heat, sweetness and acid. One week after the laser application, all of the patients in the laser group reported an improvement in symptoms and nearly 60% were free of pain. After two weeks, 87.5% of the laser group were free of pain, after four, six and twelve weeks, 94.5% were free of pain. The results of the control group differed from those of the laser group. After one week, a mild improvement was detected, and there was no further improvement in the follow-up periods. Nearly all patients reported a reappearance of the symptoms after fluoridation was stopped. The results concerning fluoride application corroborate the findings of Saxer et al. (1974).

Side-effects

Here, SnF₂ was only able to achieve limited and short-term success. In order to check possible thermal effects of laser light immediately before and after laser application and after one week, laser Doppler measurements of the pulpal blood flow of irrigated teeth were elevated. No laser-induced effect to the

pulpal blood flow was detected (Moritz et al. 1996). Six weeks after the combined application of laser light and fluoridation, SnF₂ was still detectable in the surface. Therefore, it can be assumed that the combined application of the CO₂ laser and fluoridation leads to permanent integration of fluoride into the dentine surface. With a few exceptions, patients had no pain during the therapy. Laser application was accepted without any problems (Moritz et al. 1996).

Although the combined therapy mentioned above is noted to be more effective and durable compared with the GaAlAs diode (Gerschman et al. 1994), He-Ne or Nd:YAG laser (Gelsky et al. 1993), there was no evidence of statistical clinical superiority of the CO₂ laser in the comparisons by Ipci et al. (2009). They examined how the CO₂ (1 W, cw, ten seconds) and Er:YAG (30 Hz, 60 mJ, ten seconds) lasers were used with and without fluoride. A clinical improvement in dentine hypersensitivity was achieved in all of the cases (Ipci et al. 2009).

Combination with bioactive glass

Another promising therapy method for dentine hypersensitivity is the combined use of laser light and bioactive glass (bioglass) paste. The application of hydroxyapatite, the principal inorganic constituent of the tooth, also promises rapid relief from clinical pain by complete obliteration of dentinal tubules in hypersensitive teeth (Shetty et al. 2010). Bioglass and glass-ceramics resemble human dentinal hard tissue to a large extent and are characterised by high biocompatibility (Bakry et al. 2011a; Tirapelli et al. 2010; Kuo et al. 2007). Melting the bioglass paste and its resolidification promise a homogeneous blockage of dentinal tubules and deep precipitates in the dentinal tubules, offering a prolonged therapeutic duration (Lee et al. 2005a).

From various *in vitro* investigations (SEM and FTIR analysis), it was found that DP-bioglass paste could produce a new carbonate-apatite formation at the dentinal surface as a thin protective layer and that it was also able to induce a hydroxyl-carbonate apatite deposition in open tubules (Mitchell et al. 2011; Tirapelli et al. 2010) with a sealing depth of up to 60 µm (Kuo et al. 2007). In a study by Mitchell et al. (2011), a bioglass paste with a particle size range of less than 1 µm to approximately 20 µm mixed with glycerol as a carrier was more effective in the immediate reduction in fluid conductance with resistance to acidic solutions and tooth brushing, compared with non-bioactive particles (Mitchell et al. 2011).

The combined use of the CO₂ laser and bioglass actually melted DP-bioglass paste and reached a sealing depth of 10 µm (Lee et al. 2005a). A mixture of bioglass paste with 50% phosphoric acid and CO₂ laser irradiation (0.5 W, 0.12 ms, 100 Hz, non-contact mode, one minute, energy density 136 J/cm²) can modify the surficial layer, creating a more compact layer, rich in calcium phosphate, with a thickness of 5 µm, higher mechanical properties and a penetration depth of 3 µm in the dentinal tubules (Bakry et al. 2011b).

No clinical investigations thus far

Compared with bioglass application alone, it is assumed that CO₂ laser irradiation could improve the mechanical organisation of the surficial precipitates (Bakry et al. 2011b).

Clinical investigations into the therapeutic effect of such a combined treatment are not available. One of the principal problems still is the very high temperature rise that accompanies the production of glazes with this procedure, and makes clinical application currently impossible. The temperature must be over 900 °C to form a melting glass and an even higher rise in temperature is needed to melt apatite to fuse these two components together (Lin et al. 2000b). If the glaze point could be reduced, this procedure would be conceivable as a possible treatment (Lee et al. 2005b). Maybe in the future, it will be possible to fuse a bioglass with a low melting point to enamel and/or dentine (Lin et al. 2000a).

Recently, Romano et al. (2011) analysed the morphological and temperature changes after CO₂ laser irradiation with different energy parameters (0.5 W, 1 W, 1.5 W, cw, six times for five seconds with intervals of ten seconds between for cooling, non-contact mode, sweeping movement) with and without calcium-hydroxide paste applied prior to laser treatment. Statistically significant differences were detected between laser irradiation and combined treatment, with more satisfactory closure of tubules and mineral deposition on the dentinal surface after com-

binated treatment. It is known that calcium-hydroxide paste can promote the tissue-repair process (Olsson et al. 2006) and it promises an interaction between calcium-hydroxide paste and dentine associated with the morphological changes resulting from the thermal effect of the CO₂ laser on dentine, possibly also resulting in the reduction of clinical symptoms of pain (Romano et al. 2011). With the protocols used in this study, a change of temperature in the dental pulp of 1 to 5 °C was noted, but parameters above 1 W led to carbonisation and cracks, a characteristic result of high temperature, making it unfeasible for clinical procedures (Romano et al. 2011). However, in this study, with parameters of 0.5 W in cw mode for five seconds, the temperature rise was less than 5 °C, which is assumed to be safe for clinical use (Romano et al. 2011). Nevertheless, further studies should be undertaken before clinical application. Table 1* gives an overview of the clinical studies conducted on the application of laser for the therapy of dentine hypersensitivity thus far.

Conclusion

There are many studies on the application of laser for the clinical therapy of hypersensitive tooth necks. Current evidence is based upon a slight superiority of laser application compared with conventional topical applications (He et al. 2011). *In vitro* experiments have not yet been able to clarify the mechanisms of the different application modes sufficiently. Besides analgesic effects, the modification of the dentinal surface in terms of a reduction in dentine permeability is in the foreground (Fig. 1). The latter mechanism could be enhanced by the combination of other techniques, for example the additional application of fluoride. In order to achieve optimal monitoring of the patients, the user should be familiar with the different mechanisms that the specific laser and the chosen parameters produce.

*Editorial note: *Table 1 and the list of references are available from the publisher.*

_contact	laser
<p>Dr Ute Botzenhart Department of Orthodontics Centre of Dentistry and Oral Health Ernst Moritz Arndt University of Greifswald Germany</p>	
<p>Dr Andreas Braun/Prof Matthias Frentzen Department of Periodontology, Operative and Preventive Dentistry University of Bonn Germany</p>	