

# CBCT applications in dental practice: A literature review

Authors\_ Dr Mohammed A. Alshehri, Dr Hadi M. Alamri & Dr Mazen A. Alshalhoob, Saudi Arabia

Two-dimensional imaging modalities have been used in dentistry since the first intra-oral radiograph was taken in 1896. Significant progress in dental imaging techniques has since been made, including panoramic imaging and tomography, which enable reduced radiation and faster processing times. However, the imaging geometry has not changed with these commonly used intra-oral and panoramic technologies.

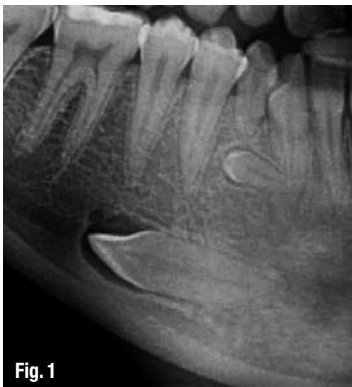

Fig. 1

Fig. 1\_Impacted teeth in close proximity to vital structures should be evaluated with CBCT.

Cone-beam computed tomography (CBCT) is a new medical imaging technique that generates 3-D images at a lower cost and absorbed dose compared with conventional computed tomography (CT). This imaging technique is based on a cone-shaped X-ray beam centred on a 2-D detector that performs one rotation around the object, producing a series of 2-D images. These images are re-constructed in 3-D using a modification of the original cone-beam algorithm developed by Feldkamp *et al.* in 1984.<sup>1</sup> Images of the craniofacial region are often collected with a higher resolution than those collected with a conventional CT. In addition, the new systems are more practical, as they come in smaller sizes.<sup>2</sup>

follow-up—of CBCT in the various dental disciplines. The goal of the following systemic review is to review the available clinical and scientific literature pertaining to different clinical application of CBCT in the dental practice.

## Materials and methods

Clinical and scientific literature discussing CBCT imaging in dental clinical applications was reviewed. A MEDLINE (*PubMed*) search from 1 January 1998 to 15 July 2010 was conducted. *Cone-beam computed tomography in dentistry* was used as key phrase to extend the search to all the various dental disciplines. The search revealed 540 papers that were screened in detail. Owing to a lack of relevance to the subject, 406 papers were excluded. Thus, the systemic review consisted of 134 clinically relevant papers, which were analysed and categorised (Table I).

## Analysis

### Oral and maxillofacial surgery

CBCT enables the analysis of jaw pathology,<sup>3-11</sup> the assessment of impacted teeth (Fig. 1), supernumerary teeth and their relation to vital structures,<sup>6,12-21</sup> changes in the cortical and trabecular bone related to bisphosphonate-associated osteonecrosis of the jaw<sup>5,22-23</sup> and the assessment of bone grafts.<sup>24</sup> It is also helpful in analysing and assessing paranasal sinuses<sup>6,25</sup> and obstructive sleep apnea.<sup>27-28</sup>

As the images are collected from many different 2-D slices, the system has proven its superiority in overcoming superimpositions and calculating surface distances.<sup>28-29</sup> This advantage made it the technique of choice in mid-face fracture cases,<sup>30-31</sup> orbital fracture assessment and management<sup>32</sup> and for inter-operative visualisation of the facial bones after fracture.<sup>33-34</sup> Since it is not a magnetic resonance technique, it is the best option for intra-operative navigation during procedures, including gun-shot wounds.<sup>35-36</sup>

Today, much attention is focused on the clinical applications—diagnosis, treatment and

Figs. 2a & b\_Perio-apical lesion shown as peri-apical radiograph (a) and CBCT (b); images courtesy of Dr Fred Barnett).

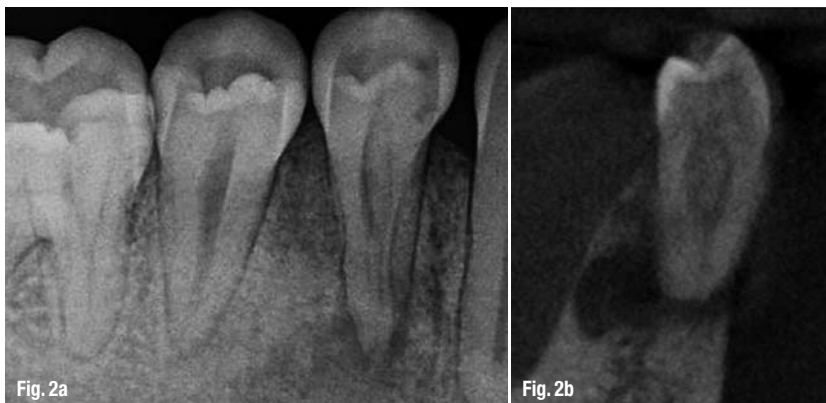


Fig. 2a

Fig. 2b

CBCT is largely used in orthognathic surgery planning when facial orthomorphic surgery is indicated that requires detailed visualisation of the inter-occlusal relationship in order to augment the 3-D virtual skull model with a detailed dental surface. With the aid of advanced software, CBCT facilitates the visualisation of soft tissue to allow for control of post-treatment aesthetics, for example in cleft palate cases to evaluate lip and palate bony depressions.<sup>37-42</sup>

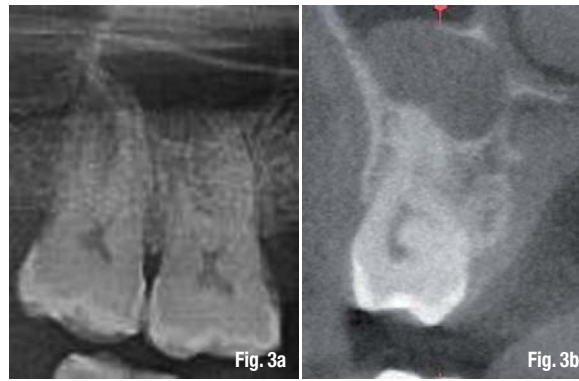Research is underway to assess its ability to detect salivary gland defects.<sup>43</sup> Honda *et al.*<sup>44</sup> describe a clinical case in which the time needed to complete a tooth auto-transplant case was significantly shortened owing to the application of CBCT.

*Endodontics*

CBCT is a very useful tool in diagnosing apical lesions (Figs. 2a & b).<sup>21,45-56</sup> A number of studies have demonstrated its ability to enable a differential diagnosis of apical lesions by measuring the density from the contrasted images of these lesions, in whether the lesion is an apical granuloma or an apical cyst (Figs. 3a & b).<sup>49,55-57</sup> Cotton *et al.*<sup>46</sup> used CBCT as a tool to assess whether the lesion was of endodontic or non-endodontic origin.

CBCT also demonstrated superiority to 2-D radiographs in detecting fractured roots. Vertical and horizontal root fracture detection is described in several clinical cases.<sup>21,46,55-59</sup> It is also agreed that CBCT is superior to peri-apical radiographs in detecting these fractures, whether they are bucco-lingual or mesiodistal.<sup>60-61</sup>

In cases with inflammatory root resorption, lesions are detected much easier in early stages with CBCT compared to conventional 2-D X-ray.<sup>21,62</sup> In other cases, such as external root resorption, external cervical and internal resorption, not only the presence of resorption was detected, but also the extent of it.<sup>21,46,54,56,63-64</sup>



**Figs. 3a & b** Apical cyst shown as orthopantomogram (a) and CBCT (b).

CBCT can also be used to determine root morphology, the number of roots, canals and accessory canals, as well as to establishing the working length and angulations of roots and

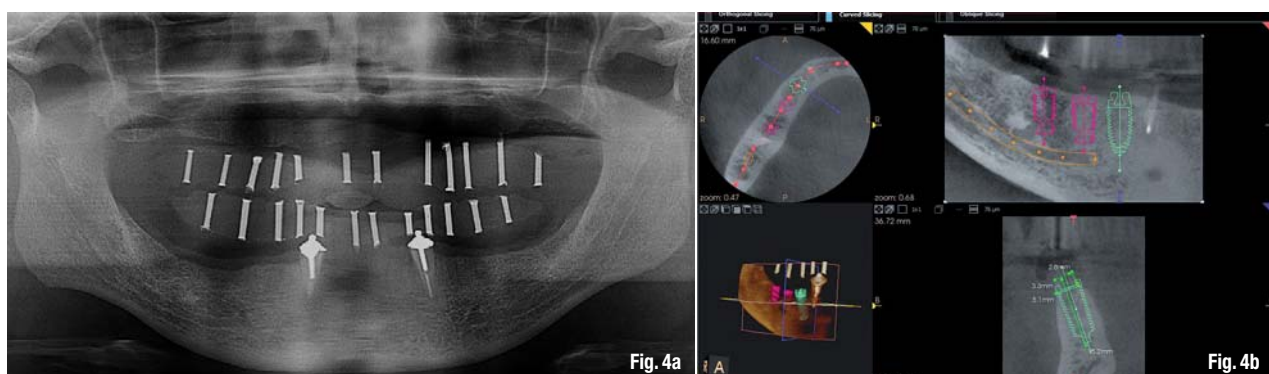
Specialty	Number of articles	in %
Oral and maxillofacial surgery	36	26.86
Endodontics	32	23.88
Implantology	22	16.42
Orthodontics	16	11.94
General dentistry	14	10.45
Temporomandibular joint disorder	8	5.97
Periodontics	5	3.73
Forensic dentistry	1	0.75

**Table I**

canals.<sup>21,25,46,55-56,58,65-67</sup> It also is accurate in assessing root-canal fillings.<sup>47,51,56,58</sup> Owing to its accuracy, it is very helpful in detecting the pulpal extensions in talon cusps<sup>68</sup> and the position of fractured instruments.<sup>69</sup>

It is also a reliable tool for pre-surgical assessment of the proximity of the tooth to adjacent vital structures, size and extent of lesions, as well as the anatomy and morphology of roots with very accurate measurements.<sup>21,46,48,50,54-58,69-72</sup>


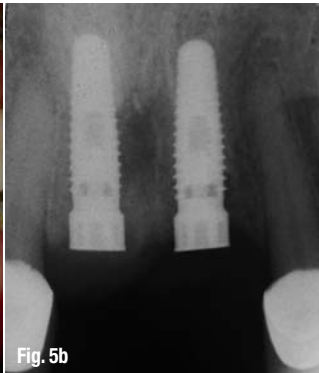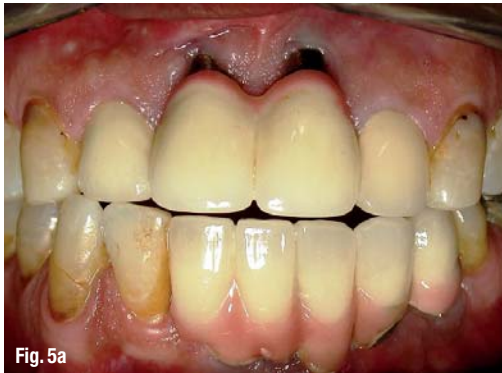
**Fig. 4a** Orthopantomogram for a full-mouth rehabilitation case. Only limited data can be obtained from this image.  
**Fig. 4b** CBCT images for the same patient. Data obtained from these images regarding bone quality, implant length and diameter, implant location and proximity to vital structures is magnificent.



Additionally, in cases in which teeth are assessed after trauma and in emergency cases, its application can be a useful aid in reaching a proper diagnosis and treatment approach.<sup>46,55,73-74</sup>

Recently, owing to its reliability and accuracy, CBCT has also been used to evaluate the

CBCT is a reliable tool in the assessment of the proximity to vital structures that may interfere with orthodontic treatment.<sup>104-105</sup> In cases in which mini-screw implants are placed to serve as a temporary anchorage, CBCT is useful for ensuring a safe insertion<sup>106-108</sup> and to assess the bone density before, during and after treatment (Fig. 6).<sup>109-110</sup>



**Fig. 5a** Clinical picture of multiple implants placed in 2005.

**Fig. 5b** Peri-apical radiograph for the implants replacing teeth #8 and #9. Little data can be collected from such an image.

**Fig. 5c** The CBCT image clearly demonstrates the amount of bone loss.

canal preparation in different instrumentation techniques.<sup>75-76</sup>

### Implantology

With increased demand for replacing missing teeth with dental implants, accurate measurements are needed to avoid damage to vital structures. This was achievable with conventional CT. However, with CBCT giving more accurate measurements at lower dosages, it is the preferred option in implant dentistry today (Figs. 4a & b).<sup>2,6,11,18,70,77-89</sup>

With new software that constructs surgical guides, damage is also reduced further.<sup>77,84,90-93</sup> Heiland *et al.*<sup>94</sup> describe a technique in which CBCT was used inter-operatively in two cases to navigate the implant insertion following microsurgical bone transfer.

CBCT enables the assessment of bone quality and bone quantity.<sup>18,26,70,80-81,85,88,95-97</sup> This leads to reduced implant failure, as case selection can be based on much more reliable information. This advantage is also used for post-treatment evaluation and to assess the success of bone grafts (Figs. 5a-d).<sup>18,88</sup>

### Orthodontics

Orthodontists can use CBCT images in orthodontic assessment and cephalometric analysis.<sup>6,70,84,98-99</sup> Today, CBCT is already the tool of choice in the assessment of facial growth, age, airway function and disturbances in tooth eruption.<sup>100-103</sup>

Having different views in one scan, such as frontal, right and left lateral, 45-degree views and sub-mental, also adds to the advantages of CBCT.<sup>111,124</sup> As the images are self-corrected from the magnification to produce orthogonal images with 1:1 ratio, higher accuracy is ensured. CBCT is thus considered a better option for the clinician.<sup>113</sup>

### Temporomandibular joint disorder

One of the major advantages of CBCT is its ability to define the true position of the condyle in the fossa, which often reveals possible dislocation of the disk in the joint, and the extent of translation of the condyle in the fossa.<sup>18,56,114</sup> With its accuracy, measurements of the roof of the glenoid fossa can be done easily.<sup>115-116</sup> Another advantage of some of the available devices is their ability to visualise soft tissue around the TMJ, which may reduce the need for magnetic resonance imaging in these cases.<sup>117</sup>

Owing to these advantages, CBCT is the imaging device of choice in cases of trauma, pain, dysfunction, fibro-osseous ankylosis and in detecting condylar cortical erosion and cysts.<sup>70,87,118-120</sup> With the use of the 3-D features, the image-guided puncture technique, which is a treatment modality for TMJ disk adhesion, can safely be performed.<sup>121</sup>

### Periodontics

CBCT can be used in assessing a detailed morphologic description of the bone because it has proved to be accurate with only minimal error

margins.<sup>56,122</sup> The measurements proved to be as accurate as direct measurements with a periodontal probe.<sup>56,123</sup> Furthermore, it also aids in assessing furcation involvements.<sup>20,56,116</sup>

CBCT can be used to detect buccal and lingual defects, which was previously not possible with conventional 2-D radiographs.<sup>56,124</sup> Additionally, owing to the high accuracy of CBCT measurements, intra-bony defects can accurately be measured and dehiscence, fenestration defects and periodontal cysts assessed.<sup>56,125-127</sup> CBCT has also proved its superiority in evaluating the outcome of regenerative periodontal therapy.<sup>124</sup>

*General dentistry*

Based on the available literature, CBCT is not justified for use in detecting occlusal caries, since the dose is much higher than conventional radiographs with no additional information gained. However, it proved to be useful in assessing proximal caries and its depth.<sup>20</sup> Table II shows examples of typical doses of various dental radiological procedures in dental practice.

*Forensic dentistry*

Many dental age estimation methods, which are a key element in forensic science, are described in the literature. CBCT was established as a non-invasive method to estimate the age of a person based on the pulp-tooth ratio.<sup>128</sup>

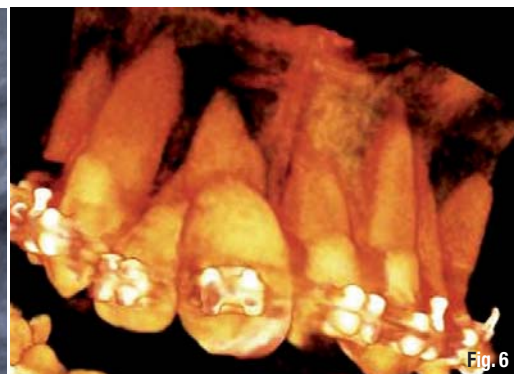
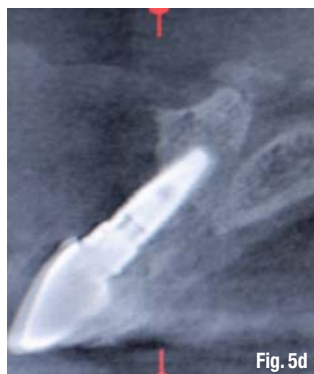**Discussion**

CBCT scanners represent a great advance in dento-maxillofacial (DMF) imaging. This technology, introduced into dental use in the late 1990s,<sup>129</sup> has advanced dentistry significantly. The number of CBCT-related papers published each year has increased tremendously in the last years. The above systematic review of the literature related to CBCT-imaging applications in dental practice was undertaken in order to summarise concisely the indications of this new image technique in different dental specialties.

*Cone-beam computed tomography in dentistry* was used as key phrase in this systemic review. Other terminology encountered in the literature, such as cone-beam volumetric scanning, volumetric computed tomography, dental CT, dental 3-D CT and cone-beam volumetric imaging, did not result in additional relevant papers.<sup>130</sup>

The clinical applications for CBCT imaging in dentistry are increasing. The results of this review

demonstrate that 134 papers were clinically relevant and that the most common clinical applications are in the field of oral and maxillofacial surgery, implant dentistry, and endodontics. CBCT has limited use in operative dentistry owing to the high radiation dose required in relation to its diagnostic value.



The literature on CBCT is promising and needs further research, especially with regard to its use in forensic dentistry, in order to explore more potentially beneficial indications in that area. No literature concerning direct CBCT indications in prosthodontics was found. However, several overlapping indications were found in other dental specialties attributing to the final standard of care in prosthodontic treatment. These indications include but are not limited to bone grafting, soft-tissue grafting, prosthetically driven implant placement, maxillofacial prosthodontics and temporomandibular joint disorder. CBCT images can also be of great value in special cases in which multiple teeth have to be assessed for restorability (Figs. 7a-e).

The latest CBCT units have a higher resolution, lower exposure, are less expensive and designed for use in dentistry. Additionally, the flat-panel detectors appear to be less prone to beam-hardening artefacts. There are, however, several important disadvantages as well, such as susceptibility to

**Fig. 5d** Total buccal plate destruction is evident in this CBCT image.

**Fig. 6** CBCT image to assess the bone density during treatment.

**Table II** Typical doses of various dental radiological procedures.

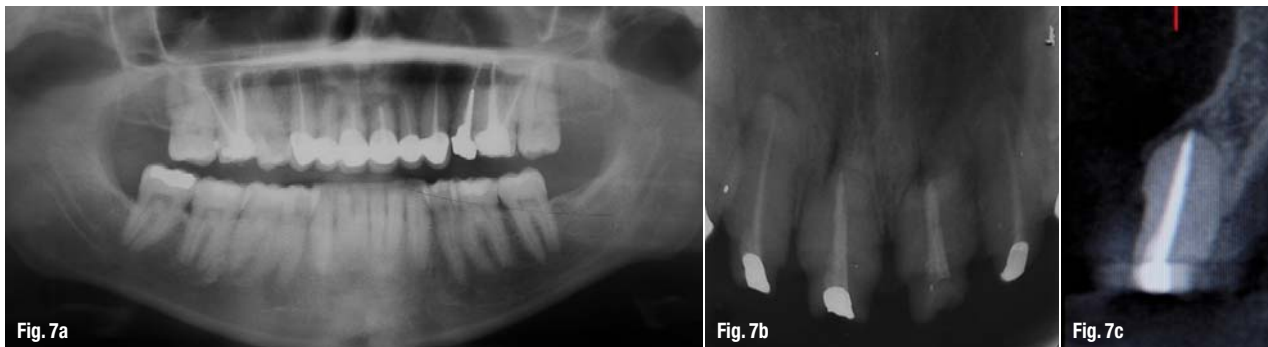
Intra-oral (F speed, rectangular collimator)	0.001 mSv
Intra-oral (E speed, round collimator)	0.004 mSv
Full-mouth set (E speed, round collimator)	0.080 mSv
Lateral cephalogram (F speed, rare-earth screen)	0.002 mSv
Dental panoramic technique (F speed, rare-earth screen)	0.015 mSv
CBCT (both jaws)	0.068 mSv
Hospital CT scan (both jaws)	0.6 mSv

**Table II**

movement artefacts, low contrast resolution, limited capability to visualise internal soft tissues and, owing to distortion of Hounsfield Units, CBCT cannot be used for the estimation of bone density.

It is crucial that the ALARA principle (As Low As Reasonably Achievable) is respected during

3. CBCT examinations should potentially add new information to aid the patient's management.
4. CBCT should not be repeated on a patient 'routinely' without a new risk/benefit assessment having been performed.
5. When accepting referrals from other dentists for CBCT examinations, the referring dentist must supply sufficient clinical information



**Fig. 7a** Multiple endodontically treated teeth with a history of peri-apical surgery.  
**Fig. 7b** Peri-apical image showing a compromised crown-to-root ratio.  
**Fig. 7c** CBCT image showing the absence of the buccal plate and a compromised palatal plate, indicating that the teeth need to be extracted and site grafting performed before implant placement.

treatment, as far as the radiation dose of CBCT imaging is concerned. CBCT imaging will improve patient care, but users have to be trained to be able to interpret the scanned data thoroughly. Dentists should ask themselves whether these imaging modalities actually add to their diagnostic knowledge and raise the standard of dental care or whether they only place the patient at a higher risk. Continuous training, education and thorough research are thus absolutely essential.

One of the most clinically useful aspects of CBCT imaging is the highly sophisticated software that allows the huge volume of data collected to be broken down, processed or reconstructed.<sup>131</sup> This makes data interpretation much more user friendly, if the appropriate technical and educational knowledge is available.

The increasing popularity of CBCT resulted in numerous CBCT-unit manufacturers, frequent presentations at conferences and an increase in published papers. This resulted in an uncontrolled and non-evidence based exchange of radiation dose values and attributed to the limited technical knowledge about medical imaging devices for new-user groups. As a result, the European Academy of DentoMaxilloFacial Radiology has developed the following basic principles on the use of CBCT in dentistry:<sup>132</sup>

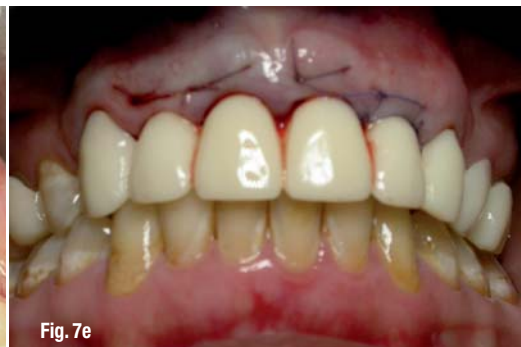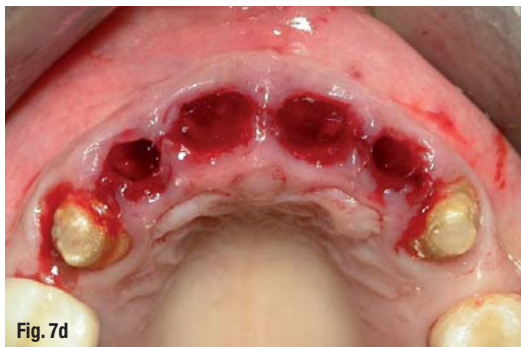1. CBCT examinations must not be carried out unless a history and clinical examination have been performed.
2. CBCT examinations must be justified for each patient to demonstrate that the benefits outweigh the risks.

(results of a history and examination) to allow the CBCT practitioner to perform the justification process.

6. CBCT should only be used when the question for which imaging is required cannot be answered adequately by lower dose conventional (traditional) radiography.
7. CBCT images must undergo a thorough clinical evaluation (radiological report) of the entire image dataset.
8. Where it is likely that evaluation of soft tissues will be required as part of the patient's radiological assessment, the appropriate imaging should be conventional medical CT or MR, rather than CBCT.
9. CBCT equipment should offer a choice of volume sizes, and examinations must use the smallest that is compatible with the clinical situation, if this provides a lower radiation dose to the patient.
10. Where CBCT equipment offers a choice of resolution, the resolution compatible with an adequate diagnosis and the lowest achievable dose should be used.
11. A quality assurance programme must be established and implemented for each CBCT facility, including equipment, techniques and quality-control procedures.
12. Aids to accurate positioning (light-beam markers) must always be used.
13. All new installations of CBCT equipment should undergo a critical examination and detailed acceptance tests before use to ensure that radiation protection for staff, members of the public and patient are optimal.
14. CBCT equipment should undergo regular routine tests to ensure that radiation protection,

for both practice/facility users and patients, has not significantly deteriorated.

15. For staff protection from CBCT equipment, the guidelines detailed in Section 6 of the European Commission document *Radiation protection 136: European guidelines on radiation protection in dental radiology* should be followed.



**Fig. 7d** Extractions done for teeth #7, 8, 9 and 10 were atraumatic and bone grafting was performed.

**Fig. 7e** Temporisation done and healing of the grafted sites for future implant placement is awaited.

16. All those involved with CBCT must have received adequate theoretical and practical training for the purpose of radiological practices and relevant competence in radiation protection.
17. Continuing education and training after qualification are required, particularly when new CBCT equipment or techniques are adopted.
18. Dentists responsible for CBCT facilities, who have not previously received 'adequate theoretical and practical training', should undergo a period of additional theoretical and practical training that has been validated by an academic institution (university or equivalent). Where national specialist qualifications in dento-maxillofacial radiology exist, the design and delivery of CBCT training programmes should involve a DMF radiologist.
19. For dento-alveolar CBCT images of the teeth, their supporting structures, the mandible and the maxilla up to the floor of the nose (for example, 8 cm x 8 cm or smaller fields of view), clinical evaluation (radiological report) should be done by a specially trained DMF radiologist or, where this is impracticable, an adequately trained general dental practitioner.
20. For non-dento-alveolar small fields of view (for example, temporal bone) and all craniofacial CBCT images (fields of view extending beyond the teeth, their supporting structures, the mandible, including the TMJ, and the maxilla up to the floor of the nose), clinical evaluation (radiological report) should be done by a specially trained DMF radio-

logist or by a clinical radiologist (medical radiologist).

### **Conclusion**

CBCT is most frequently applied in oral and maxillofacial surgery, endodontics, implant dentistry and orthodontics. CBCT examination must

not be carried out unless its medical necessity is proven and the benefits outweigh the risks. Furthermore, CBCT images must undergo a thorough clinical evaluation (radiological report) of the entire image dataset in order to maximise the benefits.

Future research should focus on accurate data with regard to the radiation dose of these units. CBCT units have small detector sizes and the field of view and scanned volumes are limited, which is the reason that CBCT units specific to orthodontic and orthognathic surgery are not yet available. Additional publications on CBCT indications in forensic dentistry and prosthodontics are also desirable.

*Editorial note: A complete list of references is available from the publisher.*

<b>_about the authors</b>	<b>CAD/CAM</b>
<p><b>Dr Mohammed A. Alshehri</b> is a Consultant for Restorative and Implant Dentistry at the Riyadh Military Hospital, Department of Dentistry and Assistant Clinical Professor at the King Saud University, College of Dentistry, Department of Restorative Dental Sciences. He can be contacted at dr_mzs@hotmail.com.</p> <p><b>Dr Hadi M. Alamri</b> and <b>Dr Mazen A. Alshalhoob</b> are interns at Riyadh Colleges of Dentistry and Pharmacy.</p>	